

## **PITYRIASIS VERSICOLOR – POSSIBLE GENETIC BASIS, PROBABLE TRANSITION FROM COMMENSALISM TO PARASITISM AND THE IMPLICATION ON TREATMENT APPROACH**

<sup>1</sup>George, A. O., <sup>1</sup>Daramola, O. O. M.

<sup>1</sup>Dermatology Division, Department of Medicine,  
University College Hospital, Ibadan Nigeria.

Correspondence to: Dr. A.O. George  
nikem95@yahoo.com or nikem95@hotmail.com

\*Current address: Dermatology division, Department of Medicine,  
University of Ilorin Teaching Hospital, Ilorin, Nigeria.

**Non-occurrence of Pityriasis versicolor (PV) in spouses of individuals with this superficial fungal infection despite several years of cohabitation suggests that heredity might play an important role in those affected. Forty subjects who were married were studied in two phases. The first phase involved using a detailed structured format to obtain information on the presence of PV in subjects, their spouses and siblings. In the second phase the family of an index case was studied over a 2-year period from a clinical and mycological aspect. Seventy percent of subjects interviewed in the first phase had at least one family member with PV. In the second phase, 4 other siblings of the index case studied all had PV. Of the 3 that were married (index case inclusive), 2 had PV but none of their spouses had. This study supports the role of heredity in the individuals with PV.**

**Keywords: Pityriasis versicolor, Hereditary, Treatment**

### **INTRODUCTION**

Pityriasis versicolor (*various colours*) (PV) is a superficial fungal skin disease presenting with finely scaly patches in 'geographical' patterns often found in areas of maximum sebum production such as the trunk, the neck, face and thighs after puberty. The observa-

tion that married adult patients who recurrently suffers from Pityriasis versicolor but whose spouses never had the entity despite many years of living together prompted a study to consider the role of hereditary and the interplay of other factors in the appearance of this clinical entity.

*Malassezia furfur* (MF) or Pity-

*rosporum orbiculair* is a commensal on the skin. The skin in up to 96% of post-pubertal adults harbours the yeast form (1). Studies of normal and affected skin of patients with PV support a dimorphic concept: that MF becomes pathologic when it changes from the yeast to a filamentous form (2). PV is rare before puberty (3). An apparent clustering of PV in families has been noted for decades and the probability of genetic basis has been postulated (4). PV is commoner in the tropics and subtropics than in the temperate countries with prevalence as high as 40% in adults in some small communities (5). There is thus a need to look more at this entity in the West African sub region.

## **SUBJECTS AND METHOD**

A predominantly epidemiological study was conducted using questionnaires. We decided to study family units. The study focused on adults and on marriages of not less than two years duration. Cohabitation of couples at least twice a week or any other prolonged skin to skin contact was the most important inclusion criterion. Information on parents, brothers,

sisters and children (where indicated) of the index PV case seen in the clinic was documented. The study excluded the extended family to ensure more reliable information. The study was carried out in two phases.

### **Phase 1**

A detailed structured questionnaire was utilized to obtain demographic data on the index cases as well as information on the presence of PV in spouses and siblings. This had the advantage regarding cost of the study and the relative ease of obtaining information. Information could be obtained on family members not physically around – while in the boarding schools, or on a job out of town. As PV fluctuates from one season to another and flares up in response to various aggravating factors, active cases may thus not always be available for physical assessment at the time of visitations to the families as in one of the cases of Robert's (4). We were encouraged in the use of questionnaires for phase one due to the ability of many people to correctly diagnose the condition in our environment. From unpublished data, in the skin

clinic at University College Hospital, Ibadan, eight out of every ten cases of PV patients were right about the diagnosis they made. PV is a well-known entity attested to by the existence of distinct names for it in many Nigerian languages (6). A few tribal names for PV in Nigeria are: 'Aikhumosele' – affliction of the beautiful in Bini (Edo), 'Ifo' – spots on light complexioned people in Yoruba, 'Ndiong' – rash of the beautiful in Efik, 'Ngwo ndi nma' – spots of the beautiful in Igbo and 'Kyasfi' – spots on young people in Hausa.

### **Phase 2**

This involved closely studying, over a 2-year period, family members of an index case thoroughly from the clinical and mycological aspects. This was considered to be essential since other cutaneous conditions like erythrasma, pityriasis rosea, atypical seborrhoeic dermatitis or dermatophytosis could be confused with PV, even by the health workers. It also allowed us to observe fluctuations and the possibility of contagion over the period. It was more demanding in term of cost and time hence the smaller number families

for this phase.

## **RESULTS**

### **Phase 1**

Of the 40 index cases (diagnosed from clinical features and mycology), 19 were males and 21 were females. They were aged 18 – 70 years. The responders have been married for 2 – 50 years. One of the sets of couples had a spouse who had PV. PV in him had been present for years, long before marriage or bodily contact with the spouse. In 70% of the index PV cases interviewed there was one or more family members (parents, children or siblings) with PV.

### **Phase 2.**

Figure 2 shows the family tree of an index case and the presence of PV over a two-year period in family members. The pattern of involvement is suggestive of some hereditary involvement.

# FIGURE 1

## PREDISPOSING FACTORS FOR PITYRIASIS VERSICOLOR.

**i) Age 0-5 yrs** Increase in (Yeast form SEBUM Colonization 0-10%)  
**ii) Age 15 yrs-Adult** (Yeast form colonization-96%)  
**(iii) Genetic Predisposition** (Aggravating factors) (A) (B) (C) (D)

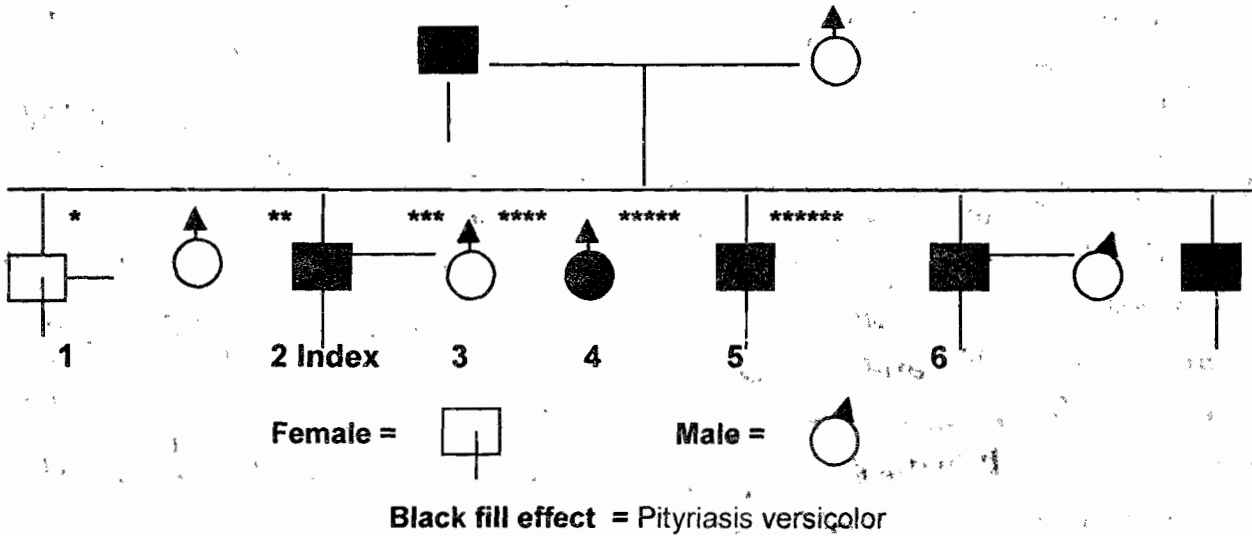
**(v) Clinical state**  
 (Pityriasis versicolor)

**(iv)**  
 (Pathogenic filamentous form.)

- (A) High humidity, heat, CO<sub>2</sub>, Sweat, occlusion (14)
- (B) Steroid (iatrogenic or Cushing's disease) (10)
- (C) Reduced body immunity-pregnancy, malnutrition, malignancy, intensive care setting (8)
- (D) More amino acids on the skin, shorter alkali neutralization time, Reduced degree of water spreading (15).

# FIGURE 2

## FAMILY OF A CASE OF PITYRIASIS VERSICOLOR STUDIED CLOSELY FOR TWO YEARS HISTORICALLY FOR PV AND WITH CLINICAL AND MYCOLOGICAL CONFIRMATION FOR PITYROSPORUM ORBICULARE



\* Siblings of the family being studied - 5 females and one male youngest = 35 years (\*\*\*\*\*)

1\* = First born 2\*\* Second born etc. of family being studied  
 2\*\* index case: age 46 years, female already married for 23 years  
 Husband still has not had pityriasis versicolor.

## DISCUSSION

The present study is a preliminary one. The advantage of the present study using questionnaire mainly, apart from financial, is the avoidance of the problem of examining women in purdah (where the husband and patient are strict moslems). Secondly a visit may not yield result since PV might have cleared in a spouse at the time of visitation, as in one of the 3 cases of Roberts (4). Clinical diagnosis of PV from our experience agrees with the patients' impression in about 8 out of every 10 cases in this environment and from a questionnaire tested before the commencement of the present study. It is thus considered justifiable to use the questionnaire in gathering of data in the study of this chronic skin disease exhibiting periods of exacerbation and remission.

In the present study, one of the patients had a spouse who had PV. It was found that he had PV long before marriage or bodily contact with the index case, the wife. It cannot be proven conclusively from this study that the current infection is not from the wife. It will require complex mycological studies to show that the strains from the

couple are the same.

The present study has limitations. There could be missed diagnosis especially where the spouses are not very observant and where the extent of the lesions is small. More positive responses i.e. the presence of PV in 70% of blood relations of the patients suggests some genetic or familial predisposition. Genetic factors have been adduced in a study (7). The continued reappearance of PV in such blood relations (who do not live with the index case after the latter has moved away following marriage for example and where spouses remain unaffected after long periods of staying together and having bodily contact) suggests more of a genetic rather than familial predisposition.

Faegerman and Fredrikson scraped apparently normal skin from 85 infants younger than 5 years of age and observed no *Pityrosporum orbiculare* (PO) colonization (1). They recovered the yeast however from 10%, 23% and 93% of children aged 5, 10 and 15 years respectively. It was postulated that the development of sebaceous gland, reaching a maximum at about puberty and increased skin

fatty acid content must account for the increased yield with age. The common site on the trunk, the onset of PV at puberty and the lipophylic nature of the organism in culture support the need for lipids for organism sustenance. Lipid content does not explain it all since infants are also affected in some special situations. Although Maples (5) did not indicate the medical status of 2 infants with PV seen in his survey of a village, the high prevalence of infants' colonization with PO appears to be unique to the intensive care setting. It was not possible to recover PO from 50 normal newborn infants within the first 3 days of life - demonstrating that PO is not perinatally transmitted (8). In contrast, skin colonization of low birth weight infants with *Candida spp.* appear to occur frequently during labour and delivery (9). The flare up of PV in pregnancy, malignancy, steroid (iatrogenic or Cushing's disease) (10) and the colonization in infants hospitalized in intensive care units suggest some relationship to the level of body immunity. Sweating and occlusion in a hot tropical setting are some of the aggravating factors and possibly contribute to

the high prevalence in some tropical areas with up to 40% in some series compared to less than 1% in temperate countries (11).

Studies of normal and affected skin of patients with PV support the dimorphic concept that *Pityrosporum orbiculare* becomes pathogenic when it changes from yeast to a filamentous form (3). Since about 95% of the skin in adults harbours the yeast form, the absence of clinical PV in the spouses of the patients screened by questionnaire in this study, as well as the presence of PV in 70% of members of the families of patients point to hereditary factors in the predisposition to the filamentous form, while the factors mentioned earlier on act as adjuncts (Fig. 1).

Pityriasis versicolor responds to most of the antifungal agents available in most countries; Whitfield ointment (Benzoic acid/salicylic acid mixture), polyenes, imidazoles, selenium sulphide, sulphur ointment, sodium thiosulphate and recently triazoles like itraconazole (sporanox). There is often recurrence however after cessation of the agents some time later either weeks or months. Even the use of ketoconazole which when

taken orally gets to all skin surfaces, removing the possibility of missed or skipped lesions does not prevent recurrence of PV. In a trial of ketoconazole by Borelli (12), 78 of 82 patients were considered cured. He concluded that this result indicated that ketoconazole is effective in the treatment of pityriasis versicolor, but problem of protecting susceptible persons from infection and re-infection remains unsolved. PV thus appears not to be readily contagious like other fungal entities e.g. dermatophytosis since the causative organism is a normal commensal in about 96% of pubertal and post pubertal individuals. It will appear that the clinical condition known as PV results from the interplay of features as shown in figure 1.

The principles/approach to treatment will thus involve: maintenance therapy (continuous or intermittent) to reduce the population of the fungi by the cheapest (i.e. effective treatment at an affordable price) and safest drugs. Griseofulvin should never be used as it has no effect whatsoever on the organism. Apart from the wasting of money, it may also result in headache (a common side effect) to

the unfortunate patient. Oral medication can be tried in extensive lesions. There will thus be no skipped areas (common with the use of topical agents) to areas beyond the reach of the patients' hands. Itraconazole and ketoconazole have been tried this wise. Ketoconazole 400 mg as a single dose for 1-2 days can be used to treat widespread infections. Fluconazole is also effective. Topical imidazole (creams) applied twice daily may be helpful but are much expensive for the developing countries. A shampoo with fungicidal activity such as ketoconazole (Nizoral shampoo by Janssen/Cilag) is good especially as it can be applied to a large area of the body including the hair. The latter harbours the causative organism (PO), as well as *Pityrosporum ovale*. Ketoconazole (Nizoral) shampoo application should be twice weekly in the first phase for a period of 2-4 weeks leaving the shampoo in contact with the skin for 5-10 minutes before rinsing. In the prophylactic phase once week application as above will be adequate. Selenium sulphide and Zinc pyrithione have also been in use. Avoidance of heat and very moist/humid areas will be

beneficial. The use of corticosteroid creams as cosmetics, a common practice in the West Africa (13) and as skin bleaching agent should be discouraged since steroids encourage proliferation of PO. Also greasy/oily cosmetic should also be avoided. Since the organism is lipophylic, the use of coconut oil on the skin has been found to increase the prevalence of PV in some villages. Good skin hygiene should be encouraged. The patient's mind should be prepared to expect the hypo or hyper pigmentation to lag behind therapy by weeks or months depending on sun tanning exposure, skin colour and other factors.

## REFERENCES

1. Faergemann J, Fredrikson T. Age incidence of *Pityrosporum orbiculare* on human skin. *Acta. Dermatol. Venereal.* 1970; **60**: 531-533.
2. McKingley KJ, Lantis LR, Marples RR. Microbiology of *Tinea versicolor*. *Arch. Dermatol.* 1970; **102**: 168-171.
3. Winner HI. Transition from commensalisms to parasitism. *Br. J. Dermatol.* 1979; **81** (1): 62-68
4. Roberts DSOB. Pityriasis versicolor. A clinical and mycological investigation. *Br. J. Dermatol.* 1969; **81**: 315-326
5. Marples MJ. The incidence of certain skin diseases in Western Samoa. A preliminary survey. *Trans. Roy. Soc. Trop. Med. Hyg.* 1950; **44**: 319-332.
6. Okoro AN. *Tinea versicolor* not eczema. *Nig. Med. J.* 1973; **3**: 47-50.
7. Hafez M, El-Shamy S. Genetic susceptibility in pityriasis versicolor. *Dermatologica.* 1985; **171**(2): 86-88.
8. Dwight A, Powell J, Durcell DE, et al. *Malassezia furfur* skin colonization of infants hospitalized in intensive care units *J. Paediatr.* 217-220.
9. Bailey JE, Kliegman RM, et al. Fungal colonization in the very low birth weight. *Paediatr.* 1986; **78**: 225-232



10. Boardman CR, Malkinson, FD. Tinea versicolor in steroid treated patients. *Arch. Dermatol.* 1962; **85**: 44-52.
11. Roberts DSOB, Mackenzie WR. Mycology. In: Rook, Wilkinson, Ebling (eds.) Textbook of Dermatology, 3<sup>rd</sup> edition, Blackwell Scientific Publication, Oxford. 1979: 767-867
12. Dante Borelli. Treatment of pityriasis versicolor with ketoconazole. *Rev. Infect. Dis.* 1980; **2(4)**: 592-595.
13. Olumide YM. Abuse of topical corticosteroids in Nigeria. *Nig. Med. Pract.* 1986; **11(1)** ;
14. Feingold DS, Taplin. Infections and infestation of the skin. *J. Am. Acad. Dermatol.* 1984; **11(5)**: 971-975.
15. Gloor M, kuempol D, Freiderich HC. Predisposing factors on the surface of the skin in persons with pityriasis versicolor. *Arch. Dermatol. Res.* 1975; **254(3)**: 281-286.